

## Eruption Pattern In Mixed Dentition In An Outpatient Pediatric Population

G. V. Venkatakarthikeswari<sup>1</sup> , Dr. Gheena S<sup>2</sup> , Dr. Sandhya<sup>3</sup>

<sup>1</sup>Saveetha Dental College and Hospitals, Saveetha Institute of Medical and Technical Sciences (SIMATS), Saveetha University, Chennai – 600077 Tamil Nadu, India

<sup>2</sup>Department of Oral Pathology, Saveetha Dental College and Hospitals, Saveetha Institute of Medical and Technical sciences (SIMATS), Saveetha University, Chennai – 600077 Tamil Nadu, India

<sup>3</sup>Senior lecturer, Department of Dental Anatomy, Saveetha Dental College and Hospitals, Saveetha Institute of Medical and Technical sciences (SIMATS), Saveetha University, Chennai – 600077 Tamil Nadu, India

---

### ABSTRACT:

**Aim:** To study the tooth eruption pattern of mixed teeth among the pediatric population

**Background:** To compare the eruption times determined with previous studies. To see the variation of eruption time of every tooth and appraise if any preponderance exists within the eruption timings of maxillary and mandibular teeth between both boys and girls.

**Materials and Methods:** This was a descriptive cross sectional study. A random sample of 20 Pediatric children in the age between 8-9 years were selected. The mean age of eruption of mixed teeth was recorded and data were analyzed by using SPSS software version 23.

**Results:** 36.84% of kids (8-9 years) showed altered patterns of tooth eruption in mixed dentition. The study population included 11 boys constituting 45% and 9 girls constituting 55% of the total sample. Generally girls showed early tooth eruption compared to boys. Mandibular teeth erupted previously compared to maxillary teeth in both the male and female. Right and left sided teeth erupted at the constant time in each of the arches.

**Conclusion:** Thus the study documents a paediatric population with deviated chronological pattern of eruption. Further investigation on the subject can generate data to help the clinicians in treatment.

**Keywords:** Age, boys, eruption, girls, mandible, maxilla, Tooth, Novel analysis.

---

## **INTRODUCTION:**

Teeth are the important morpho biological markers which erupt into the oral cavity and help to chew and bite food(1). Histological evolution of humans has influenced the eruption pattern of teeth (2). Tooth eruption is a process in tooth development in which the tooth enters into the oral cavity and becomes visible(3). Nowadays it is currently believed that periodontal ligament plays a main role in tooth eruption(4). Estimation of eruption schedules are often a really valuable asset in diagnosis and treatment planning during developmental years (5). Tooth

Eruption recognized as a facet of human growth and development could possibly be influenced by both physiological and pathological issues like malnutrition, caries, heredity etc (6).

Permanent teeth generally erupt when children are about 6 years aged (7). Baby teeth will gradually wobble and fall out as the child grows and develops(8). All baby (deciduous) teeth are going to be replaced by permanent teeth before your child is 12 or 13 years old. This transition period is named the "Mixed Dentition Stage" (9) . Mixed dentition is a developing period in which both deciduous and permanent teeth have erupted in the oral cavity.

The deciduous tooth eruption is basically present in the following order are, central incisor, lateral incisor, first molar, canine, second molar (10). Generally girls showed early tooth eruption compared to boys(11). Mandibular teeth erupted previously compared to maxillary teeth in both the male and female.

Delayed tooth eruption mainly caused by local factors like insufficient space in dental arch or dental injection, ectopic positioning most often affects third molar, second premolar and canine because these are the last teeth which are going to erupt(12). Misalignment of teeth is called malocclusion. Abnormal or delayed tooth eruption commonly occurs in infants with developing disorders like hypopituitarism etc(13,14). Our team has extensive knowledge and research experience that has translate into high quality publications

(4),(7),(8),(15),(11),(12),(16),(17),(18),(19),(20),(21),(22),(23),(24),(1),(25),(26),(27),(28)

The aim of this study is to create awareness on tooth eruption patterns of mixed dentition among the pediatric population(29).

## **MATERIALS AND METHODS:**

A cross sectional study was conducted for 20 pediatric participants. The present study was carried out retrieving OPGs in a simple random sampling method. The examination commenced from maxillary central incisor, lateral incisor, first incisor and followed by mandibular central incisor, lateral incisor, first molar. A tooth with any of its parts emerging through the gingiva was considered to have erupted. Childrens who all have a history of malnutrition, infectious disease were excluded from the study. All questions were tabulated in excel sheets and statistical analysis was performed in Statistical Package for the Social Science (SPSS) software version 23. Descriptive statistics was performed followed by Pearson's Chi-square.

## **RESULT:**

The study population consisted of 20 pediatric participants in an age group of 8-9 years old (fig.1). In the age group of 5 years, one of the permanent teeth was found to have erupted. In the age group of 14 years, all the permanent teeth except the third molar(wisdom teeth) had erupted. 36.84% of kids (8-9 years) showed altered patterns of tooth eruption in mixed dentition.

The participants consisted of 20 school students; 11 male (55%) and 9 female( 45%) [Figure :1]. The altered patterns of tooth eruption was assessed in the age group of 8-9 years old kids [Figure :2].The percentage of maxillary central incisor present is 95 % and absent 5% [Figure :3]. The percentage of maxillary lateral incisor present is 65%, absent 20% and 5% bud missing, absent on the right side and absent on both sides [Figure :4]. The percentage of maxillary first molars being present is 85% and 5% absent on the left side, right side and both sides [Figure :5]. The percentage of mandibular central incisors is present 95% and 5% absent [Figure :6]. The percentage of mandibular lateral incisors is present 70% and 15% absent on the right side, 10 % absent on left side and 5% absent on both sides [Figure :7]. The percentage of mandibular first molars present 100 % [Figure :8].

The above bar graph represents the frequency of children with presence of maxillary central incisor teeth in the gender category. In these conditions, males with presence of maxillary central incisor teeth are 55% and females with presence of maxillary central incisor are 40% and 5% are absent of maxillary central incisor. The P value = 0.25 ( $P > 0.05$ ) statistically not significant. In these conditions, males with presence of maxillary central incisor teeth are 55% and females with presence of maxillary central incisor are 40% and 5% had absence of maxillary central incisor. The P value = 0.25 ( $P > 0.05$ ) statistically not significant [Figure:9]. The above bar graph represents the frequency of childrens in

whom maxillary lateral incisor teeth are present and are in the gender category. In these conditions, males with presence of maxillary lateral incisor teeth are 25% , bud missing 5% , absent 15% , absent on the right side 5% , absent on both sides 5% . In females with the presence of maxillary lateral incisor 40% present and 5% absent . The P value = 0.33 ( $P>0.05$ ) statistically not significant [Figure :10]. The above bar graph represents the frequency of childrens with presence of maxillary first molar teeth in the gender category. In these conditions, male with presence of maxillary first molar teeth are 45% and absent on the left side 5% , absent on both sides 5% and females with presence of maxillary first molar are 40%, absent on the right side 5% . The P value=0.40 ( $P>0.05$ ) statistically not significant [Figure :11]. The above bar graph represents the frequency of children with the presence of mandibular central incisor teeth mentioned in the gender category. In these conditions, males with the presence of mandibular central incisor teeth are 55% . In females presence of mandibular central incisor is observed in 40% and absent 5% . The P value=0.25 ( $P>0.05$ ) statistically not significant [Figure :12]. The above bar graph represents the frequency of childrens with presence of mandibular lateral incisor teeth mentioned in the gender category. In these conditions, males with presence of mandibular lateral incisor teeth are 40% , absent on the right side 5% , absent on the left side 5% and absent on both sides 5%. In females with presence of mandibular lateral incisor are 30% and absent on the right side 10% , 5% absent on the left side. The P value= 0.69 ( $P>0.05$ ) statistically not significant [Figure :13]. The above bar graph represents the frequency of children with presence of mandibular first molar teeth mentioned in the gender category. No statistics are computed because the mandibular first molar is a constant [Figure :14].

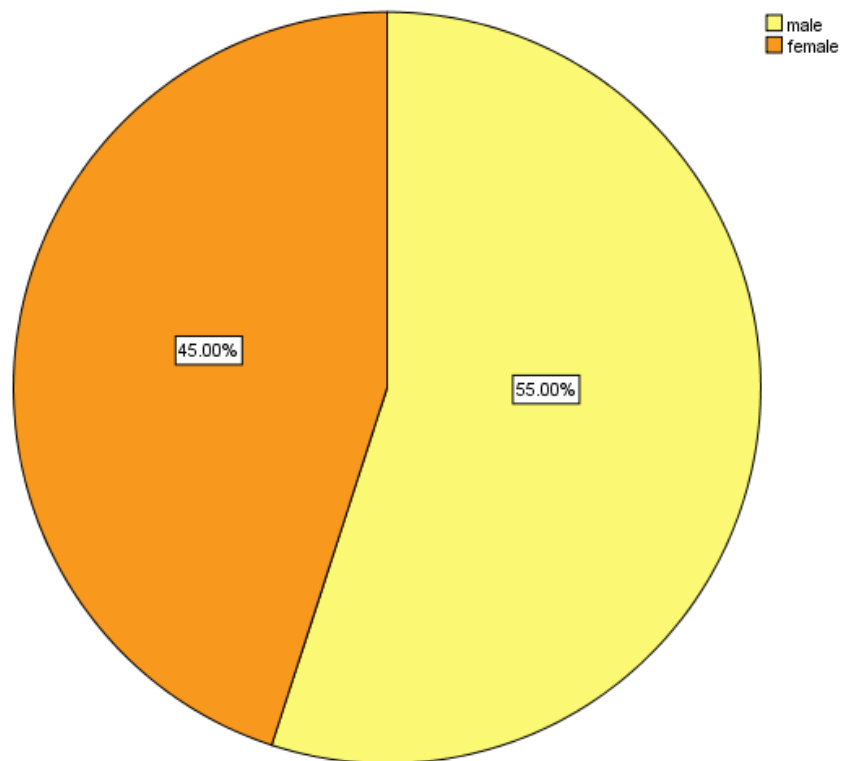


Figure 1: The above pie chart represents the status of gender distribution. Yellow colour denotes male and orange colour denotes female. Male (55%) seems to be more than female(45%).

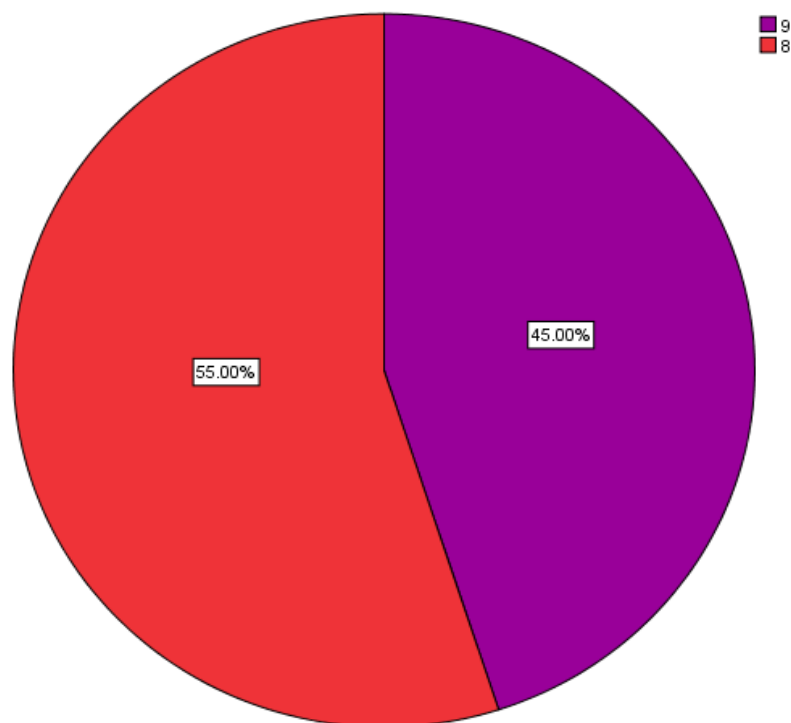


Figure 2: The above pie chart represents the percentage mentioned the status of age distribution. Red colour denotes 8 years and purple colour denotes 9 years. In this age group only 8 years old childrens (55%) and 9 years old childrens (45%) were taken among the pediatric participants.

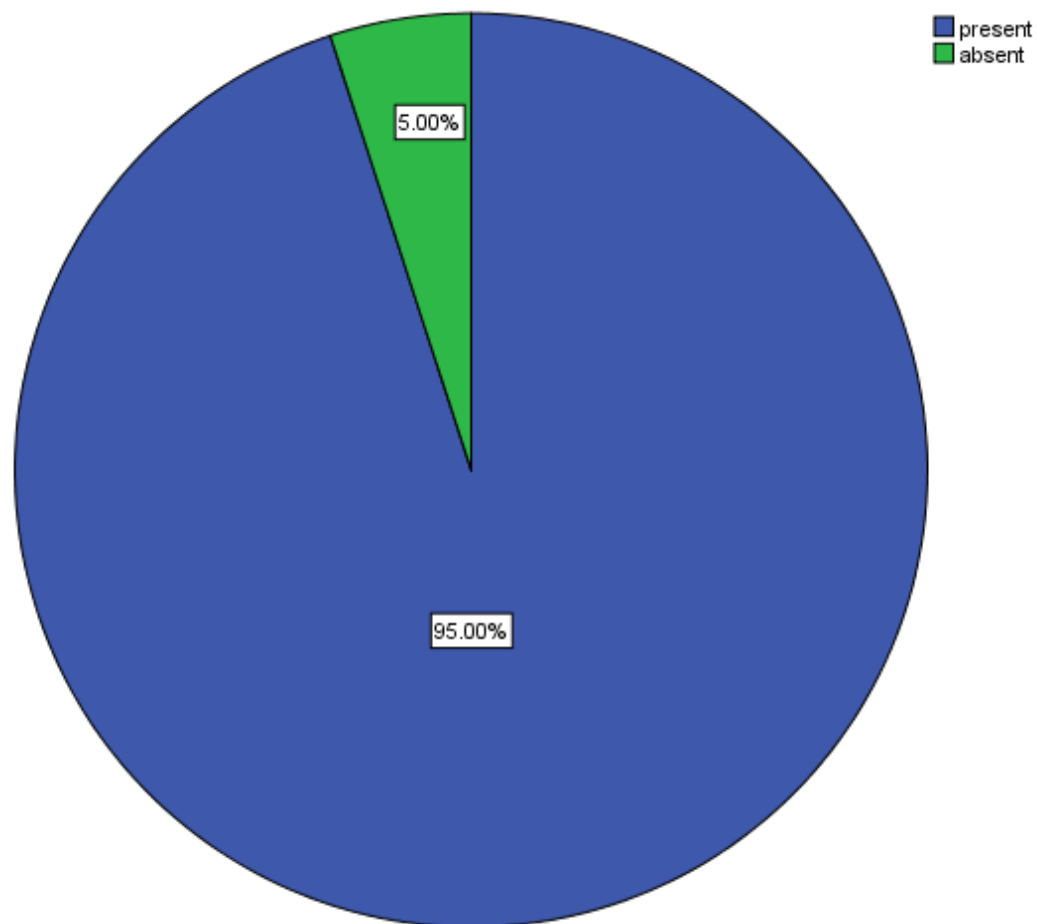


Figure 3: The above pie chart represents the percentage status of the maxillary central incisor. Blue colour denotes present and green colour denotes absent. In 95% of study participants, the maxillary central incisor was present. In 5% of them, maxillary central incisor participants were absent.

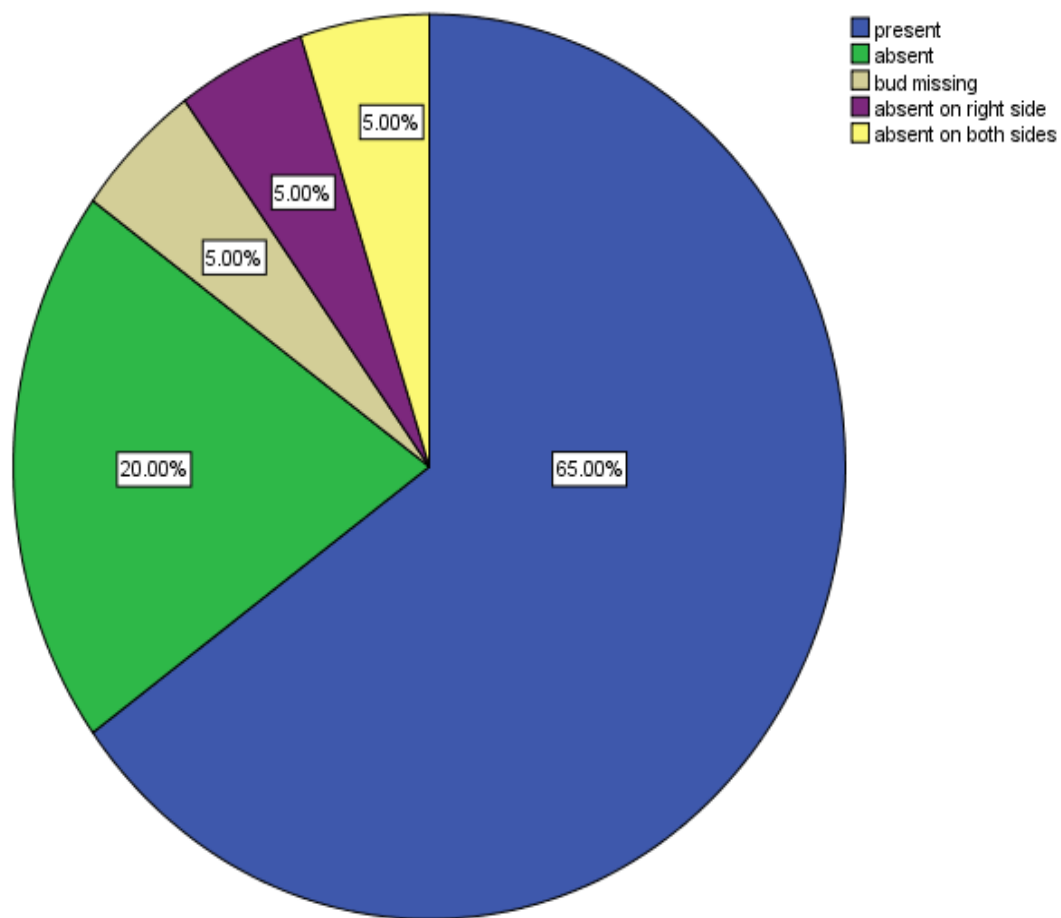


Figure 4: The above pie chart represents the status of maxillary lateral incisor in the study participants. Blue colour denotes present, green colour denotes absence, grey colour denotes bud missing, purple colour denotes absence on right side, yellow colour denotes absence on both sides. In 65% of the study participants, the maxillary lateral incisor was present. In 20% of them, the maxillary lateral participants were absent. In 5% of them, the maxillary lateral incisor participants were missing, absent on right side, absent on both sides.



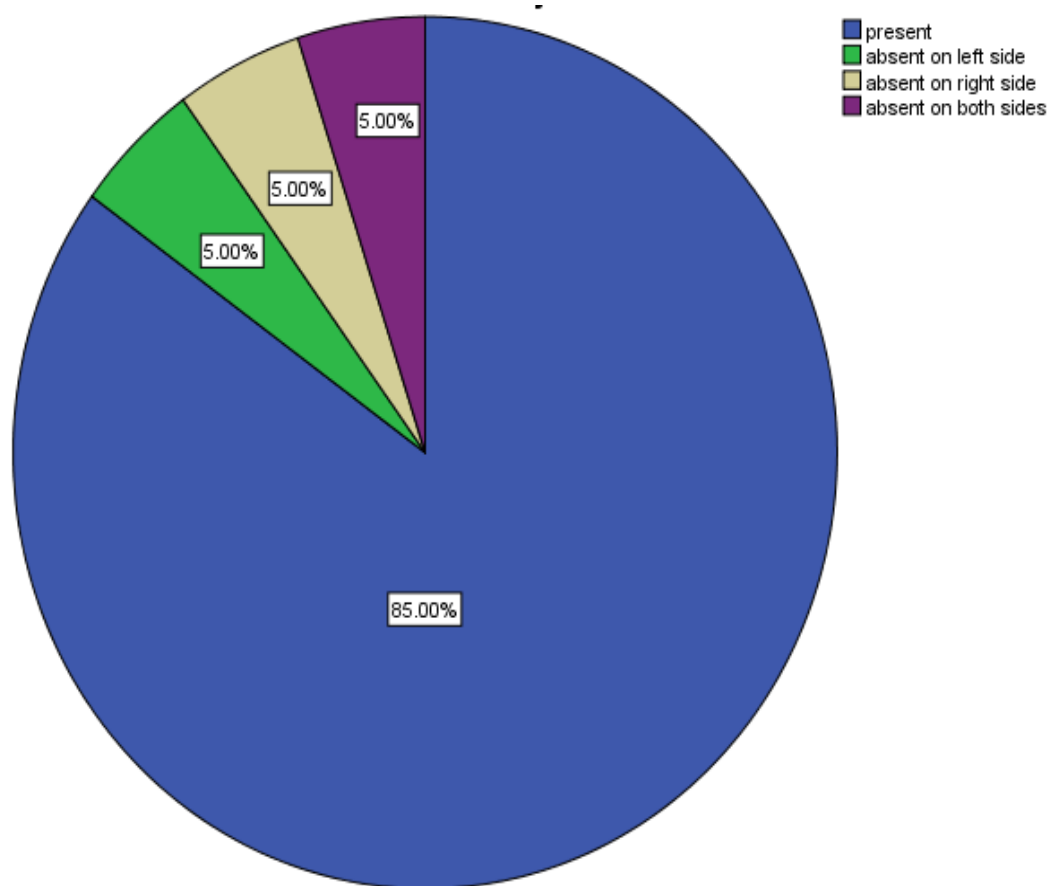


Figure 5: The above pie chart represents the status of maxillary first molar in the study participants. Blue colour denotes presence, green colour denotes absence on left side (5%), grey colour denotes absence on right side (5%), purple colour denotes absence on both sides (5%). In 85% of the study participants, the maxillary first molar was present.

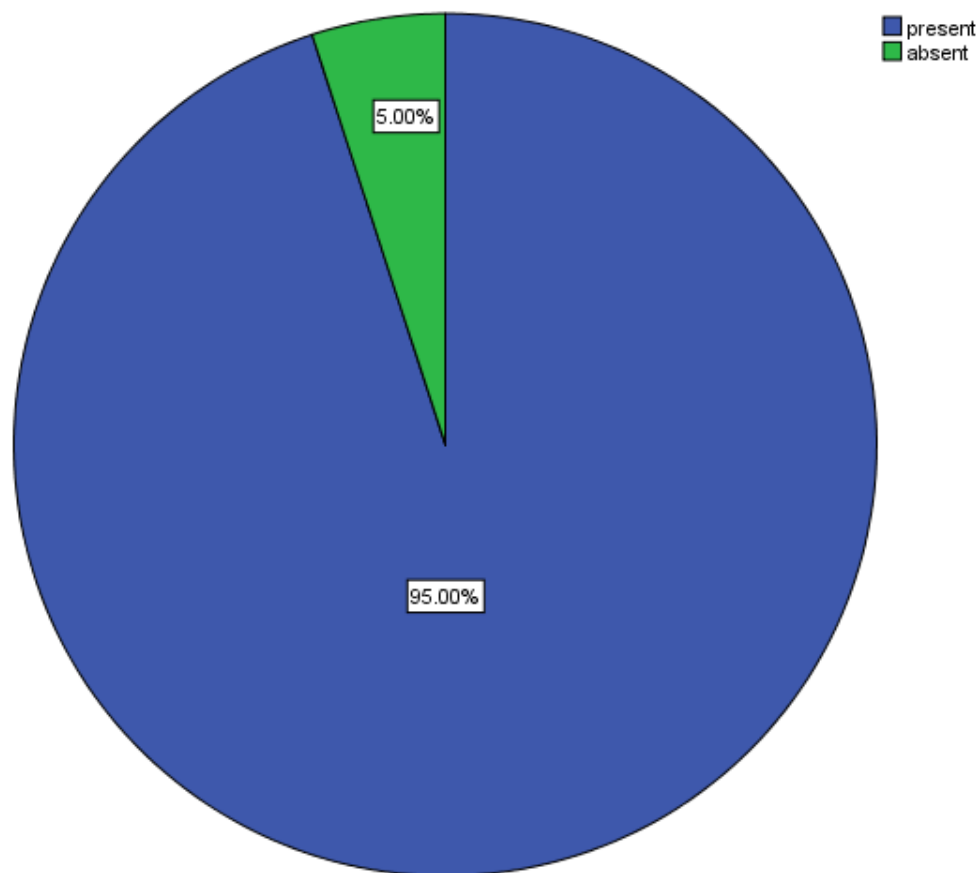


Figure 6: The above pie chart represents the mandibular central incisor. Blue colour denotes present(95%) and green colour denotes absent(5%).

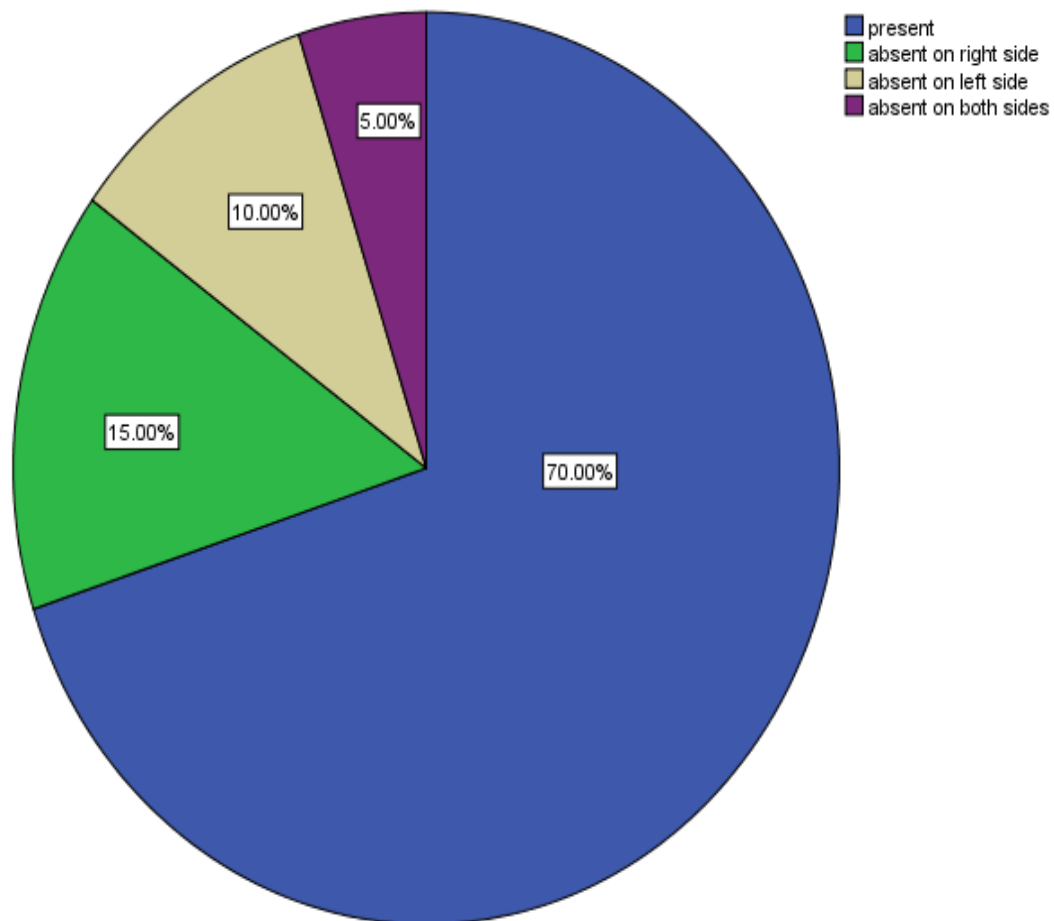


Figure 7: The above pie chart represents the presence of mandibular lateral incisors. Blue colour denotes present(70%), green colour denotes absent on right side(15%), grey colour denotes absent on left side(10%) and purple denotes absent on both sides(5%).

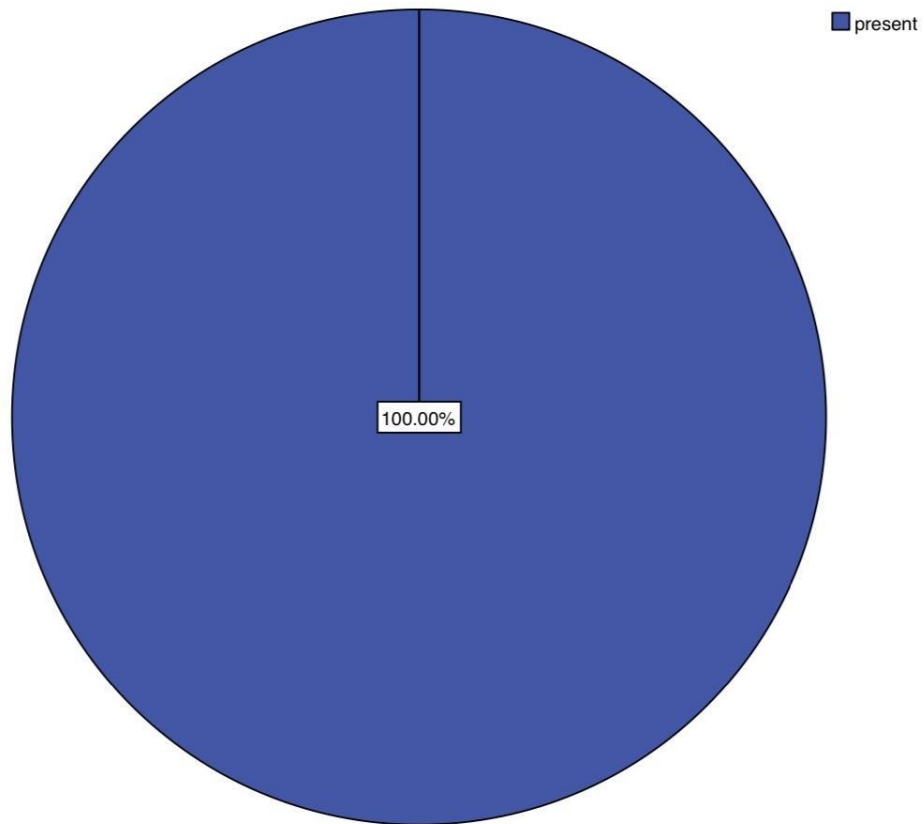


Figure 8: The above pie chart represents the status of the mandibular first molar is 100% present (blue).

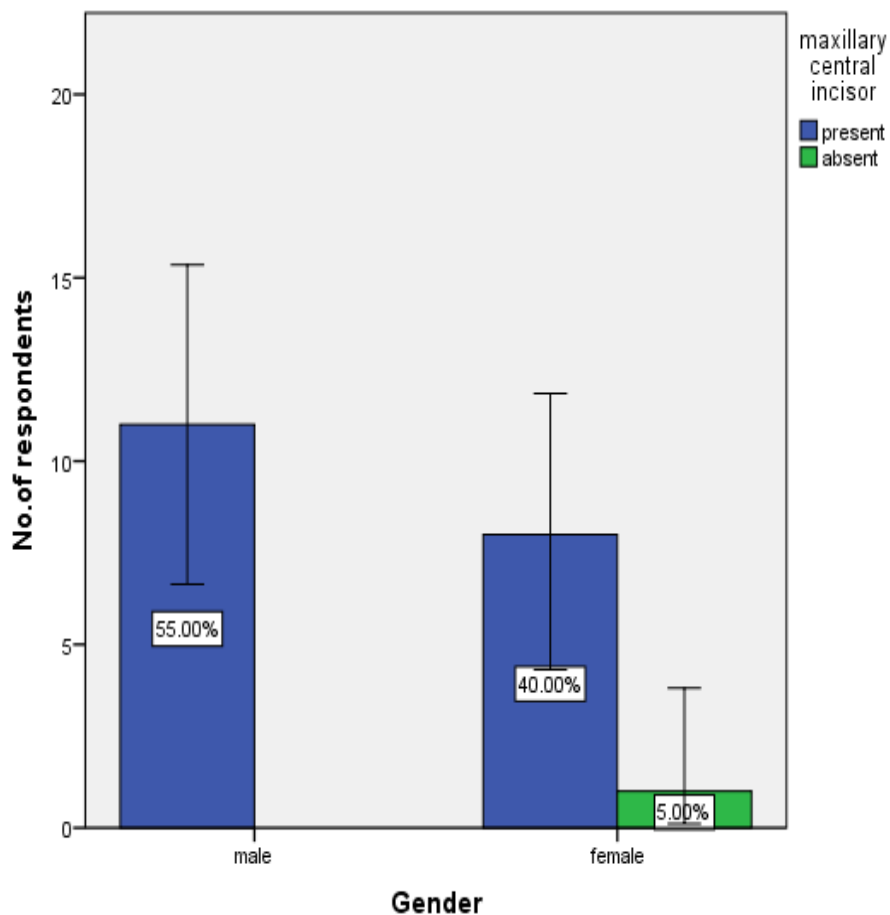


Figure 9: The above bar graph represents the frequency of children with maxillary central incisor teeth mentioned in the gender category. The x-axis represents the gender and the y-axis represents the respondents. In these conditions, males with presence of maxillary central incisor teeth are 55% (blue) and females with presence of maxillary central incisor are 40% (blue) and 5% (green) are absent of maxillary central incisor. The P value = 0.25 ( $P > 0.05$ ) statistically not significant implying that the presence or absence of maxillary central Incisor is not very evident in gender.

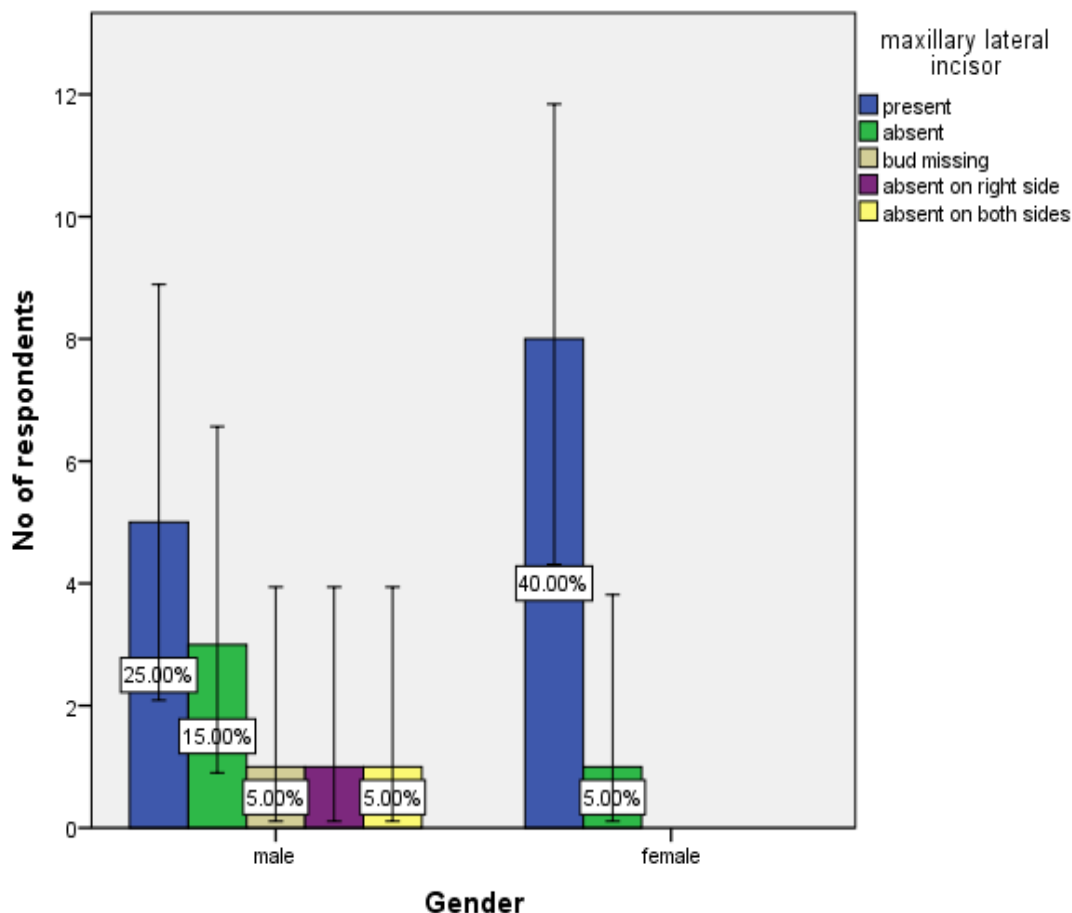


Figure 10: The above bar graph represents the frequency of childrens with presence of maxillary lateral incisor teeth mentioned in the gender category. The x-axis represents the gender and the y-axis represents the number of people responding for this survey. In these conditions, males with presence of maxillary lateral incisor teeth are 25% (blue), bud missing 5% (grey), absent 15%(green), absent on the right side 5%(purple), absent on both sides 5% (yellow). In females with the presence of maxillary lateral incisor 40% present (blue) and 5% absent (green). The P value = 0.33 ( $P > 0.05$ ) statistically not significant implying that the presence or absence of maxillary lateral Incisor is not hugely different in the gender group.

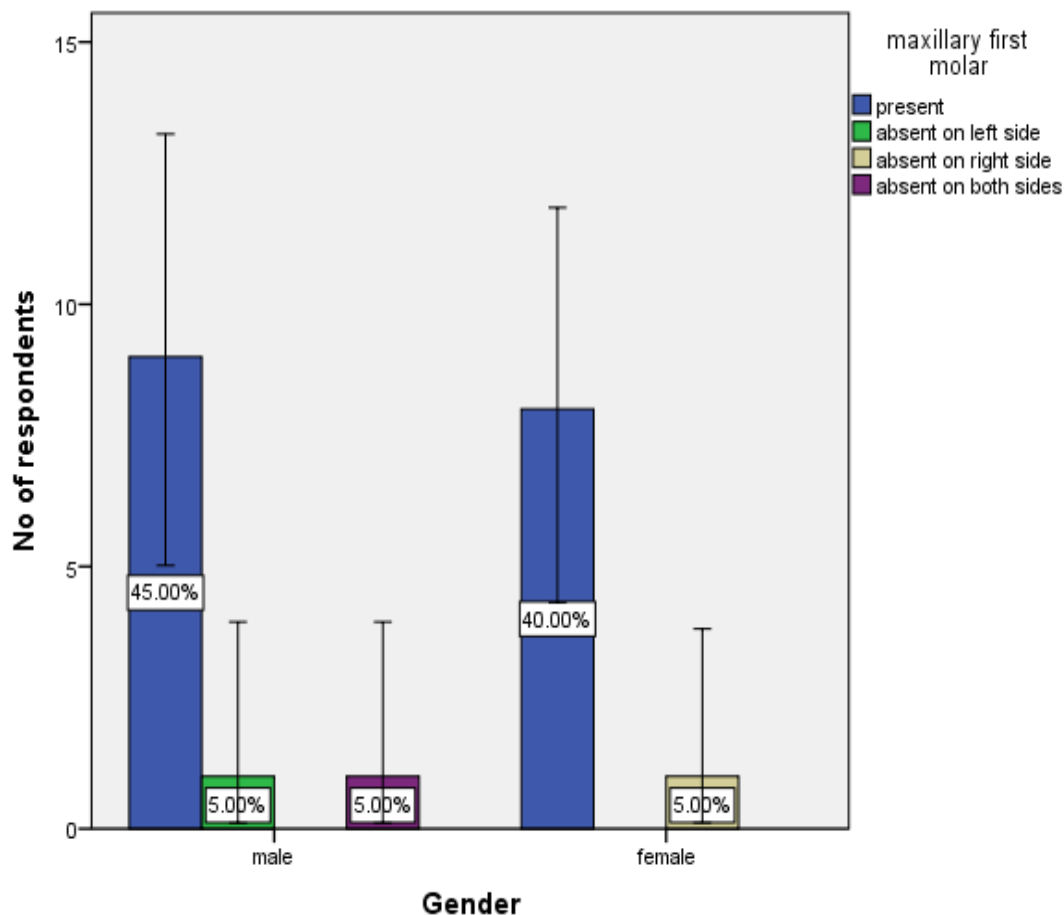


Figure 11: The above bar graph represents the frequency of children with presence of maxillary first molar teeth mentioned in the gender category. The x-axis represents the gender and the y-axis represents the number of people responding for this survey. In these conditions, male with presence of maxillary first molar teeth are 45% (blue) and absent on the left side 5% (green), absent on both sides 5% (purple) and females with presence of maxillary first molar are 40% (blue), absent on right side 5% (grey). The P value=0.40 ( $P>0.05$ ) statistically not significant implying that the presence or absence of max.first molar is not hugely different in gender group.

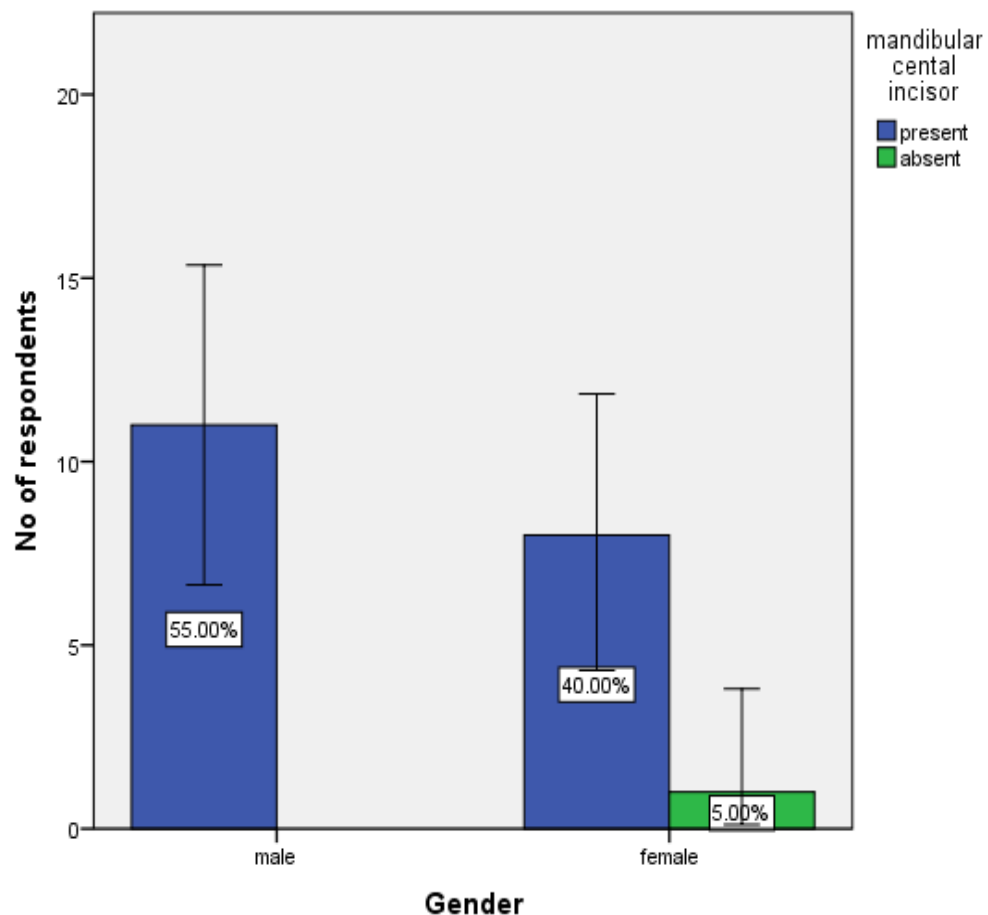


Figure 12: The above bar graph represents the frequency of childrens with presence of mandibular central incisor teeth mentioned in the gender category. The x-axis represents the gender and the y-axis represents the number of respondents. In these conditions, males with presence of mandibular central incisor teeth are 55% (blue) . In females presence of mandibular central incisor is observed in 40% (blue) and absent 5% (green). The P value=0.25 ( $P>0.05$ ) statistically not significant implying that the presence or absence of mandibular central incisor is not hugely different in the gender group.



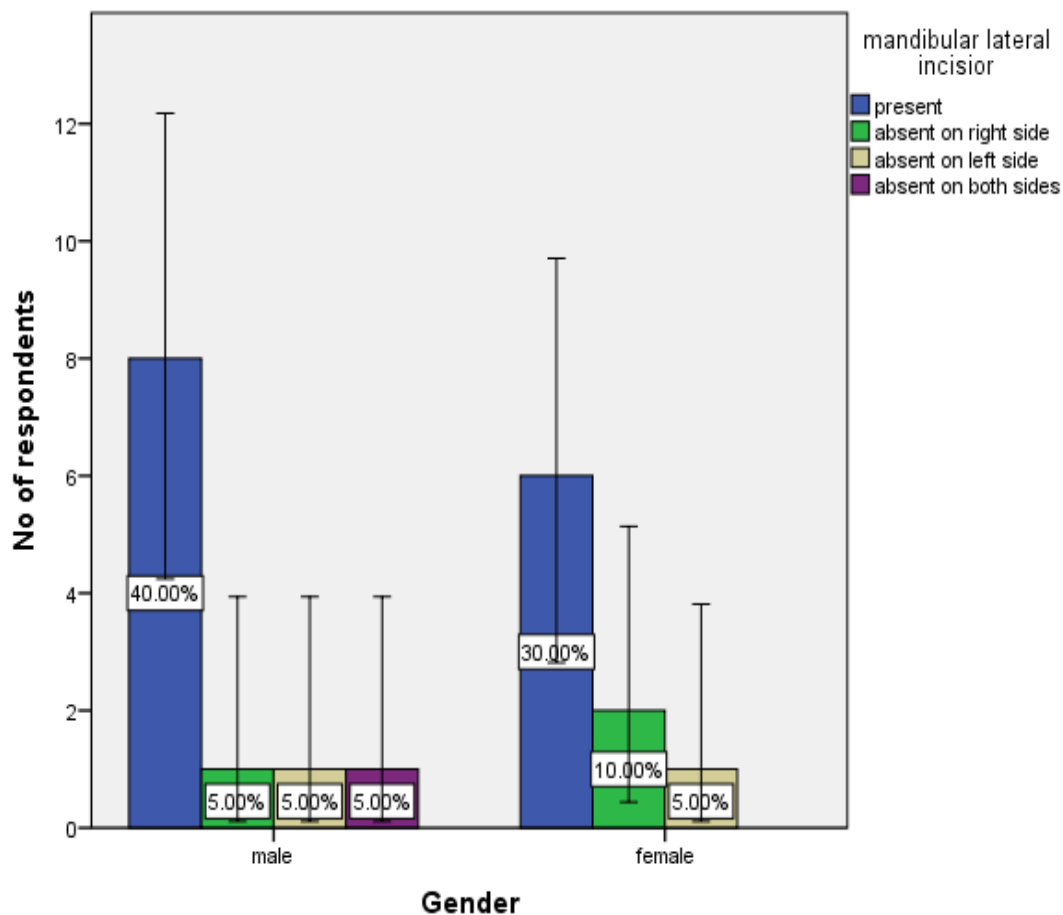


Figure 13: The above bar graph represents the frequency of children with presence of mandibular lateral incisor teeth mentioned in the gender category. The x-axis represents the gender and the y-axis represents the number of respondents. In these conditions, males with presence of mandibular lateral incisor teeth are 40% (blue), absent on the right side 5% (green), absent on the left side 5% (grey) and absent on both sides 5% (purple). In females with presence of mandibular lateral incisor are 30% (blue) and absent on the right side 10% (green), 5% absent on the left side (grey). The P value= 0.69 ( $P > 0.05$ ) statistically not significant implying that the presence of mandibular central incisor is not hugely different in the gender group.

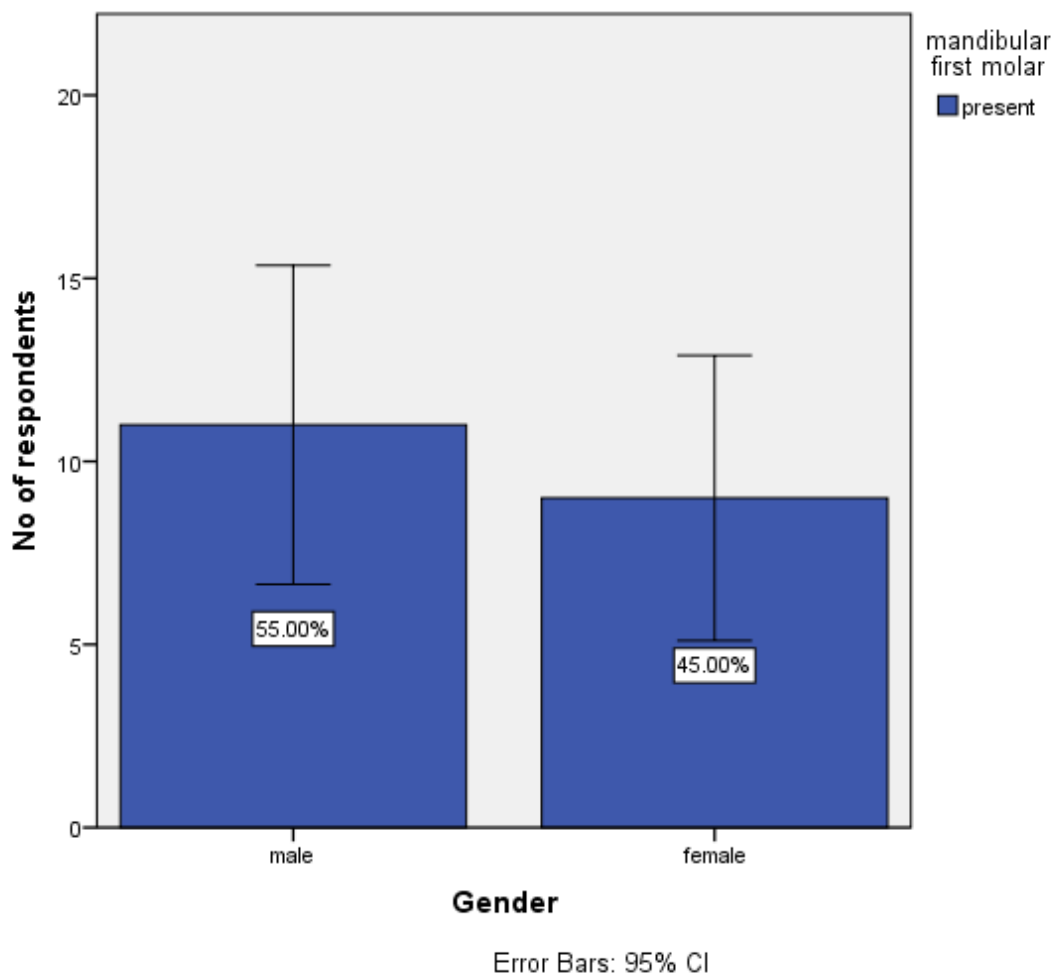


Figure 14: The above bar graph represents the frequency of childrens with presence of mandibular first molar teeth mentioned in the gender. The x-axis represents the gender and the y-axis represents the number of people responding for this survey. No statistics are computed because the mandibular first molar is constant.

#### DISCUSSION:

The present study proved that sometimes childrens have early or late tooth eruption due to some calcium deficiency, genetics, infections etc(18,30). In the previous article, natal and neonatal teeth(overview of literature) says that the natal and neonatal teeth diagnosis need detailed case history accompanied by clinical and radiographic examination of an infant (31).

In the current study average age group of 8-9 years old childrens were taken, the typical eruption pattern among central incisors in both maxillary and mandibular region which shows delay due to some local factors like insufficient space in dental arch, ectopic positioning etc (32,33). In the previous study , average age of eruption of deciduous central incisor was  $11.4 \pm 3.43$  months, whereas in the study of singh et al, conducted by in Amritsar, India, the typical age of eruption of central incisors was 8.67 months, which showed delayed eruption in our population(34) .The primary dentition completely erupted by 30 months, which was in congruent with this study.

In the current study the average eruption pattern of lateral maxillary and mandibular incisors is 6-7 and 7-8 years some of them having delayed lateral incisors due to no tooth bud development, genetic, health issues(35). According to ujwala, The frequency of missing upper lateral incisors is predominantly more in females compared to male population among their study in the age group of 12 to 18 years old(20). Furthermore in one skeletal category disorder has prevalence of bilateral missing lateral incisors is higher as compared to left and right unilateral expression(36).

In the current study the average eruption pattern of maxillary first molar tooth 6-9 years and mandibular first molar tooth 6-9 years which is sometimes delayed due to deficiency, developed syndromes etc. No statistics are computed because the mandibular first molar is constant(21). In a previous article Impacted third molars square measure ordinary encounters in routine practice. The impaction rate is higher for third molars compared with alternate teeth. The jaw third molar impaction wedge teeth might have symptoms or could also be related to numerous pathologies like tooth decay pericoronitis, cysts, tumors, of the adjacent tooth(37).

Limitation and future scope: Due to the short time period of the study, sample size was less. Further larger studies are conducted to establish the fact.

**CONCLUSION:** Thus the study documents a paediatric population with deviated chronological patterns of eruption. Few interesting observations were made which can have an impact on future treatment. Though there are differences in the eruption age between the genders it turned out to be statistically not significant. This may be due to the study being conducted on a small sample size. Further investigation on the subject in a large sample can generate data to help the clinicians in treatment.

#### **AUTHOR CONTRIBUTIONS**

Author 1: Venkatakarthikeswari, carried out the study by collecting data and drafted the manuscript after performing the necessary statistical analysis and in the preparation of the manuscript.

Author 2: Dr. Gheena S, aided in conception of the topic, designing the study and supervision of the study, correction and final approval of the manuscript.

Author 3: Dr. Sandhya, aided in conception of the topic, designing the study and supervision, correction, preparation of the manuscript, and final approval of the manuscript.

#### **ACKNOWLEDGEMENT**

Saveetha Dental College and Hospitals, Saveetha Institute of Medical and Technical Science, Saveetha University

#### **CONFLICT OF INTEREST**

All the authors declare that there was no conflict of interest in the present study.

#### **SOURCE OF FUNDING:**

The present study was supported by the following agencies

- Saveetha Dental College,
- Saveetha Institute of Medical and Technical Science,
- Saveetha University
- Pushpavain hospital

#### **REFERENCES:**

1. Zafar A, Sherlin HJ, Jayaraj G, Ramani P, Don KR, Santhanam A. Diagnostic utility of touch imprint cytology for intraoperative assessment of surgical margins and sentinel lymph nodes in oral squamous cell carcinoma patients using four different cytological stains. *Diagn Cytopathol*. 2020 Feb;48(2):101–10.
2. Lakshmappa A, Guledgud MV, Patil K. Eruption times and patterns of permanent teeth in school children of India. *Indian J Dent Res*. 2011 Nov;22(6):755–63.
3. Madiraju G, Basavaraja H. A Cross-sectional Study of Eruption Time of Primary Teeth in South

- Indian Children [Internet]. JOURNAL OF CLINICAL AND DIAGNOSTIC RESEARCH. 2020. Available from: <http://dx.doi.org/10.7860/jcdr/2020/43250.13492>
4. Princeton B, Santhakumar P, Prathap L. Awareness on Preventive Measures taken by Health Care Professionals Attending COVID-19 Patients among Dental Students. *Eur J Dent.* 2020 Dec;14(S 01):S105–9.
  5. Verma N, Bansal A, Tyagi P, Jain A, Tiwari U, Gupta R. Eruption Chronology in Children: A Cross-sectional Study. *Int J Clin Pediatr Dent.* 2017 Jul;10(3):278–82.
  6. B K, Krishnan B, John L. A CROSS - SECTIONAL STUDY OF ERUPTION PATTERN OF TEETH IN 10 - 12 YEAR OLD CHILDREN [Internet]. Vol. 4, *Journal of Evolution of Medical and Dental Sciences.* 2015. p. 7381–6. Available from: <http://dx.doi.org/10.14260/jemds/2015/1070>
  7. Mathew MG, Samuel SR, Soni AJ, Roopa KB. Evaluation of adhesion of *Streptococcus mutans*, plaque accumulation on zirconia and stainless steel crowns, and surrounding gingival inflammation in primary molars: randomized controlled trial. *Clin Oral Investig.* 2020 Sep;24(9):3275–80.
  8. Sridharan G, Ramani P, Patankar S, Vijayaraghavan R. Evaluation of salivary metabolomics in oral leukoplakia and oral squamous cell carcinoma. *J Oral Pathol Med.* 2019 Apr;48(4):299–306.
  9. Djaharu'ddin I. Prediction Formula of Permanent Canine and Premolar Eruption in Mixed Dentition Patients at Universitas Airlangga, Dental Hospital Surabaya, Indonesia. *Contemp Clin Dent.* 2019 Jan;10(1):105–9.
  10. Patil GB. A Changing Trend In Eruption Age and Pattern of First Deciduous Tooth: Correlation to Feeding Pattern [Internet]. JOURNAL OF CLINICAL AND DIAGNOSTIC RESEARCH. 2014. Available from: <http://dx.doi.org/10.7860/jcdr/2014/6987.4161>
  11. Antony JVM, Ramani P, Ramasubramanian A, Sukumaran G. Particle size penetration rate and effects of smoke and smokeless tobacco products - An invitro analysis. *Heliyon.* 2021 Mar;7(3):e06455.
  12. Sarode SC, Gondivkar S, Sarode GS, Gadbail A, Yuwanati M. Hybrid oral potentially malignant disorder: A neglected fact in oral submucous fibrosis. *Oral Oncol.* 2021 Jun 16;105390.

13. Cardesa A, Slootweg PJ, Gale N, Franchi A. Pathology of the Head and Neck. Springer; 2017. 854 p.
14. Kumar S, Agarwal N, Mehrotra A. Evaluation of skeletal maturity in North Indian subjects using an objective method based on cervical vertebral bone age and assessment of its reliability as compared to hand wrist radiographic method [Internet]. Vol. 50, Journal of Indian Orthodontic Society. 2016. p. 3–7. Available from: <http://dx.doi.org/10.4103/0301-5742.175704>
15. R H, Hannah R, Ramani P, Ramanathan A, Jancy MR, Gheena S, et al. CYP2 C9 polymorphism among patients with oral squamous cell carcinoma and its role in altering the metabolism of benzo[a]pyrene [Internet]. Vol. 130, Oral Surgery, Oral Medicine, Oral Pathology and Oral Radiology. 2020. p. 306–12. Available from: <http://dx.doi.org/10.1016/j.oooo.2020.06.021>
16. Hannah R, Ramani P, WM Tilakaratne, Sukumaran G, Ramasubramanian A, Krishnan RP. Author response for “Critical appraisal of different triggering pathways for the pathobiology of pemphigus vulgaris—A review” [Internet]. Wiley; 2021. Available from: <https://publons.com/publon/47643844>
17. Chandrasekar R, Chandrasekhar S, Sundari KKS, Ravi P. Development and validation of a formula for objective assessment of cervical vertebral bone age. Prog Orthod. 2020 Oct 12;21(1):38.
18. Subramanyam D, Gurunathan D, Gaayathri R, Vishnu Priya V. Comparative evaluation of salivary malondialdehyde levels as a marker of lipid peroxidation in early childhood caries. Eur J Dent. 2018 Jan;12(1):67–70.
19. Jeevanandan G, Thomas E. Volumetric analysis of hand, reciprocating and rotary instrumentation techniques in primary molars using spiral computed tomography: An in vitro comparative study. Eur J Dent. 2018 Jan;12(1):21–6.
20. Ponnulakshmi R, Shyamaladevi B, Vijayalakshmi P, Selvaraj J. In silico and in vivo analysis to identify the antidiabetic activity of beta sitosterol in adipose tissue of high fat diet and sucrose induced type-2 diabetic experimental rats. Toxicol Mech Methods. 2019 May;29(4):276–90.
21. Sundaram R, Nandhakumar E, Haseena Banu H. Hesperidin, a citrus flavonoid ameliorates hyperglycemia by regulating key enzymes of carbohydrate metabolism in streptozotocin-induced diabetic rats. Toxicol Mech Methods. 2019 Nov;29(9):644–53.

22. Alsawalha M, Rao CV, Al-Subaie AM, Haque SKM, Veeraraghavan VP, Surapaneni KM. Novel mathematical modelling of Saudi Arabian natural diatomite clay. *Mater Res Express*. 2019 Sep 4;6(10):105531.
23. Yu J, Li M, Zhan D, Shi C, Fang L, Ban C, et al. Inhibitory effects of triterpenoid betulin on inflammatory mediators inducible nitric oxide synthase, cyclooxygenase-2, tumor necrosis factor- $\alpha$ , interleukin-6, and proliferating cell nuclear antigen in 1, 2-dimethylhydrazine-induced rat colon carcinogenesis. *Pharmacogn Mag*. 2020;16(72):836.
24. Shree KH, Hema Shree K, Ramani P, Herald Sherlin, Sukumaran G, Jeyaraj G, et al. Saliva as a Diagnostic Tool in Oral Squamous Cell Carcinoma – a Systematic Review with Meta Analysis [Internet]. Vol. 25, *Pathology & Oncology Research*. 2019. p. 447–53. Available from: <http://dx.doi.org/10.1007/s12253-019-00588-2>
25. Karunagaran M, Murali P, Palaniappan V, Sivapathasundharam B. Expression and distribution pattern of podoplanin in oral submucous fibrosis with varying degrees of dysplasia – an immunohistochemical study [Internet]. Vol. 42, *Journal of Histotechnology*. 2019. p. 80–6. Available from: <http://dx.doi.org/10.1080/01478885.2019.1594543>
26. Sarode SC, Gondivkar S, Gadbail A, Sarode GS, Yuwanati M. Oral submucous fibrosis and heterogeneity in outcome measures: a critical viewpoint. *Future Oncol*. 2021 Jun;17(17):2123–6.
27. Raj Preeth D, Saravanan S, Shairam M, Selvakumar N, Selestina Raja I, Dhanasekaran A, et al. Bioactive Zinc(II) complex incorporated PCL/gelatin electrospun nanofiber enhanced bone tissue regeneration. *Eur J Pharm Sci*. 2021 May 1;160:105768.
28. Prithiviraj N, Yang GE, Thangavelu L, Yan J. Anticancer Compounds From Starfish Regenerating Tissues and Their Antioxidant Properties on Human Oral Epidermoid Carcinoma KB Cells. In: *PANCREAS. LIPPINCOTT WILLIAMS & WILKINS TWO COMMERCE SQ, 2001 MARKET ST, PHILADELPHIA ...*; 2020. p. 155–6.
29. Kim S-G, Kim M-H, Chae C-H, Jung Y-K, Choi J-Y. Downregulation of matrix metalloproteinases in hyperplastic dental follicles results in abnormal tooth eruption [Internet]. Vol. 41, *BMB Reports*. 2008. p. 322–7. Available from: <http://dx.doi.org/10.5483/bmbrep.2008.41.4.322>

30. Reisner H. Pathology: A Modern Case Study. McGraw Hill Professional; 2014. 672 p.
31. Anton E, Doroftei B, Grab D, Forna N, Tomida M, Nicolaiciuc OS, et al. Natal and Neonatal Teeth: A Case Report and Mecanistical Perspective. Healthcare (Basel) [Internet]. 2020 Dec 4;8(4). Available from: <http://dx.doi.org/10.3390/healthcare8040539>
32. Alsani A, Balhaddad AA. Delayed Eruption of Maxillary Central Incisors Associated with the Presence of Supernumerary Teeth: A Case Report with 18 Months Follow-up. J Contemp Dent Pract. 2018 Dec 1;19(12):1434–6.
33. Singer A, Galan E. Palygorskite-Sepiolite: Occurrences, Genesis and Uses. Elsevier; 2000. 351 p.
34. Singh V, Sharma B, Singh S, Sharma K, Suraj KP, Mahmood T, et al. Methodology of Seasonal Waves of Respiratory Disorders survey conducted at respiratory outpatient clinics across India [Internet]. Vol. 37, Lung India. 2020. p. 100. Available from: [http://dx.doi.org/10.4103/lungindia.lungindia\\_466\\_19](http://dx.doi.org/10.4103/lungindia.lungindia_466_19)
35. Tang X, Yu J, Li M, Zhan D, Shi C, Fang L, et al. Inhibitory effects of triterpenoid betulin on inflammatory mediators inducible nitric oxide synthase, cyclooxygenase-2, tumor necrosis factor- $\alpha$ , interleukin-6, and proliferating cell nuclear antigen in 1,2-dimethylhydrazine-induced rat colon carcinogenesis [Internet]. Vol. 16, Pharmacognosy Magazine. 2020. p. 841. Available from: [http://dx.doi.org/10.4103/pm.pm\\_516\\_19](http://dx.doi.org/10.4103/pm.pm_516_19)
36. Paruchuri U, Swarnalatha C, Babu J, Alquraishi M, Almalaq S, Alnasrallah F, et al. Prevalence of congenitally missing upper lateral incisors in an orthodontic adolescent population [Internet]. Vol. 9, journal of orthodontic science. 2020. p. 15. Available from: [http://dx.doi.org/10.4103/jos.jos\\_28\\_19](http://dx.doi.org/10.4103/jos.jos_28_19)
37. Santosh P. Impacted mandibular third molars: Review of literature and a proposal of a combined clinical and radiological classification [Internet]. Vol. 5, Annals of Medical and Health Sciences Research. 2015. p. 229. Available from: <http://dx.doi.org/10.4103/2141-9248.160177>